

## **BREEDING SOUNDNESS EXAMINATION**

Although the term breeding soundness examination (evaluation) is commonly used worldwide to describe the process of examination of breeding bulls also called Pre-Breeding Examination (**PBE**).

A **PBE aims** to try to identify bulls that are potentially unfit for use as breeding bulls to avoid herd fertility losses. The PBE is to help identify bulls that are infertile or potentially subfertile and a bull certified as “Suitable for Breeding” whilst not guaranteed to be of normal fertility should be of considerably less risk than a bull that has not been examined before breeding.

### **Facilities required for carrying out PBE:**

1. The bull can be securely restrained to allow access to the sheath and scrotum then a variety of crushes or races can be used.
2. A rump bar is recommended to reduce the risk of being kicked when measuring and palpating the testicles.
3. A non-slip floor surface such as a rubber mat will prevent bulls from losing their footing during EEJ.
4. If bulls are restrained in a neck yoke, care should be taken to ensure the cervical spine is not being excessively squeezed which could lead to ataxia when released from the crush.
5. The bull should have the ability to move backward and forward during EEJ and not be pushed too far forward by a rump bar.

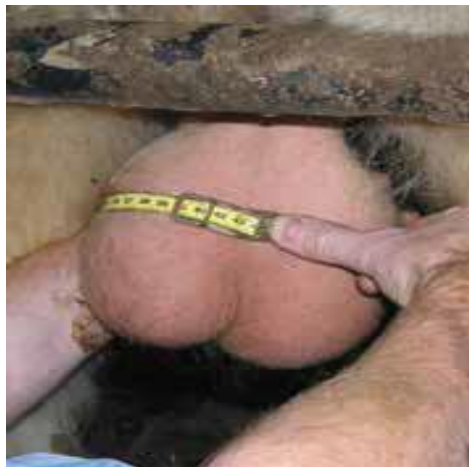

*Figure 1 Restriction of the bull before the examination*

## **Equipment required for PBE**

### **1. Scrotal Tape**

A purpose-made scrotal measuring tape should be used to ensure accuracy and consistency made from metal or plastic tape (Reliabull™). The Reliable tape has a device to ensure the same pressure is applied each time when measuring but in general, the tape should be pulled tight around the widest part of the scrotum until the skin is indented.



*Figure 1 Scrotal tape*

2. **Electro-ejaculator (EEJ) machine or Artificial Vagina (AV):** For semen collection.



*Figure 3 Electro-ejaculator (EEJ) machine*

3. **Microscope:**

For examination of semen a good quality, the well-serviced microscope is required ideally with x10, x20, x40, and x100 (oil) lenses fitted.

4. **Heated Stage**

A heated stage is essential to ensure sperm motility is not compromised by cooling of samples during the examination. Even pre-warmed slides will chill rapidly when placed on a normal microscope stage especially in cold ambient or draughty conditions.

5. **Warm Box and Laboratory Materials**

A portable incubator acts as a useful container for carrying the miscellaneous equipment required for semen examination. A checklist of things that should be carried in the warm box is:

1. Microscope slides (plain and frosted ends)
2. Coverslips – large size
3. Permanent marker pen (fine tip)

4. Slide carrier boxes
5. Nigrosine-eosin stain
6. Methylene blue stain
7. Micro-pipettes or insulin injection syringes
8. Small vials of sterile saline
9. Semen collection tubes with screw tops.

## 6. Recording Forms

Standard recording forms should be used to record the findings of each stage of the examination.

## I. PHYSICAL EXAMINATIONS

This part of the PBE aims to identify any physical abnormalities that could compromise the bull's fertility or give rise to heritable defects in its progeny.

### a) Body Condition Score (BCS):

This is assessed on a five-point scale with 1 being very thin and 5 obese. Bulls that are in BCS 2 or less should be deemed unsatisfactory in this section as they are unlikely to be able to perform adequately during an intensive breeding period. Bulls that are **obese** may suffer from poor semen quality due to deposition of fat in the scrotum leading to thermo-regulation problems and this will become apparent in the next stage of the examination when semen is assessed.

### b) General Clinical Examination:

A PBE is not intended to be a full clinical examination however for certification or insurance purposes the heart and lungs should be auscultated to eliminate the presence of any abnormalities. The eyes should be examined for lesions that could compromise vision such as cataracts, corneal opacity, or carcinoma. The

incisor/dental pad alignment should be checked for evidence of any significant pro/brachygnathia.

## II. MUSCULOSKELETAL SYSTEM

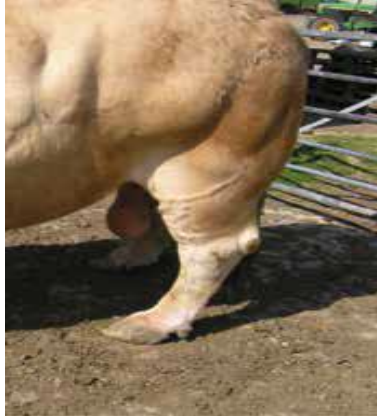Many bulls are culled prematurely due to problems with the musculoskeletal system so problems with the feet or legs must be indented if possible, at PBE to prevent these bulls from being selected as sires. Bulls should be observed walking on a smooth level surface to check for evidence of lameness and the limbs carefully inspected for any conformation defects. Although some conformational defects may not be causing lameness on the day of the examination, many have a hereditary component or will lead to lameness at a later date and thus will render bulls unsuitable for certification. Some examples of common musculoskeletal problems that can be indented during bull PBE are shown below.

### 1) **Post-Legged conformations:**

Post-legged conformation is associated with an increased risk of lameness due to hock, stifle or hip joint pathology, and young bulls showing this conformation should be avoided. Bulls with extreme post-legged conformation should not be carried as suitable for breeding.

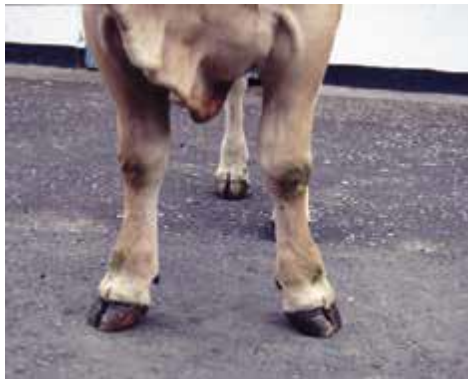### 2) **Sickle Hock:**

The opposite extreme – sickle hock will lead to collapsed heels and overgrown claws with a tendency for foot lameness and thus bulls with extreme sickle hock are unsuitable for certification.



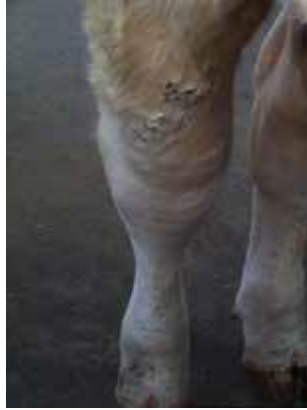### **3) Valgus Deformity of Forelimbs**

Young bulls with obvious valgus deformity will tend to develop abnormal claw overgrowth of the fore-feet and have ongoing problems.



### **4) Swollen Hocks (tarsitis):**

Swollen hocks due to excessive synovial fluid. Distension of the hock joint may be caused by osteochondrosis which if mild may not be causing any lameness. Progression to osteochondritis dissecans (OCD) is possible in some bulls however if distended hock joints are present in the absence of lameness. Bulls with swollen hocks due to OCD are likely to be lame and will be deemed unsuitable for breeding.



### 5) Corkscrew Claw and Inter-digital Fibroma (corns):

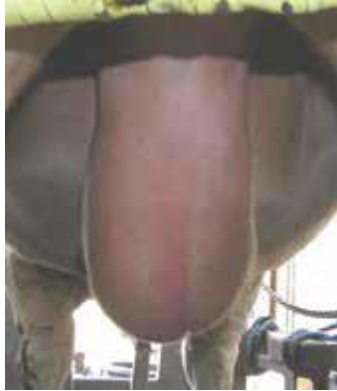Both of these foot conditions can cause lameness and ongoing problems during the life of a bull. Due to the hereditary nature of these problems then bulls should not be certified as suitable for breeding.

## III. EXAMINATION OF SCROTUM AND CONTENTS

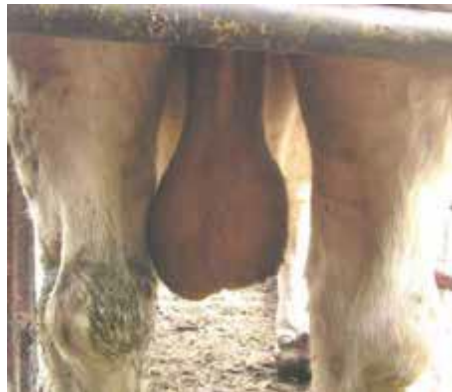### A. Examination of Scrotal Shape

Before handling the scrotum and testicles, a visual appraisal of the scrotal shape should be carried out. In a cold environment, this may be difficult as the dartos muscle of the scrotal wall and the cremaster muscles will pull the testicles closer to the body wall. In warm conditions with the dartos and cremaster relaxed, the scrotal shape can be assessed more easily. The three common descriptors for scrotal shape are:

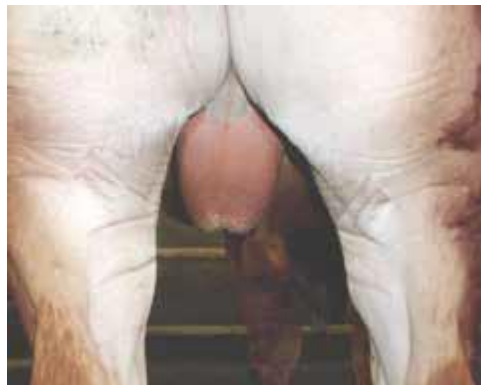- ❖ Straight (slab) sided scrotum: may be associated with small testicles and excessive fat in the neck of scrotum.



- ❖ Normal scrotum: a pendulous scrotum with a well-defined neck is ideal for the thermoregulation of testicles.



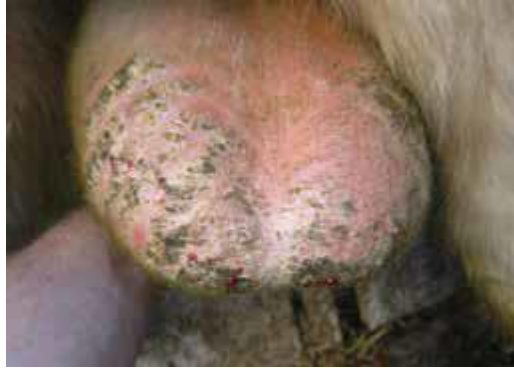- ❖ Wedge-shaped scrotum: this is associated with smaller testicles and excess fat in the neck which will be detrimental to thermoregulation and semen quality.



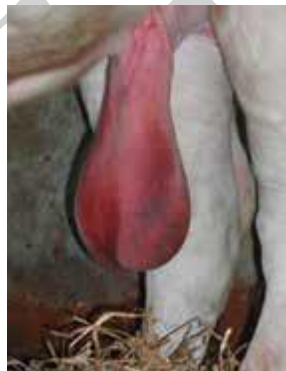#### IV. Palpation of the Scrotum and Contents



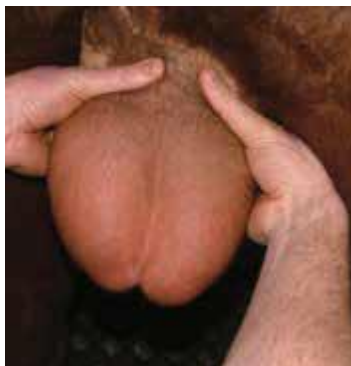The scrotal skin should be smooth and elastic and the testicles should move freely within it. Chronic thickening of the skin at the base of the scrotum may be caused by trauma or mange and if inflamed may cause heating of the testicles or a tendency for them to be held up high in the scrotum.



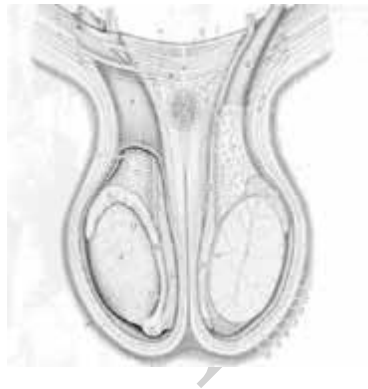
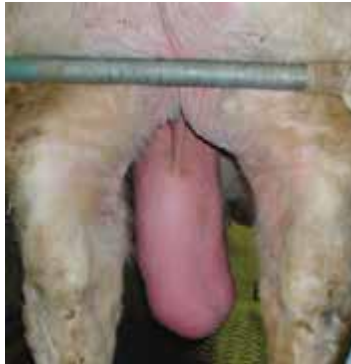Acute photo-sensitization can cause edema and swelling of the scrotum and contents.



The neck of the scrotum should be palpated from the body wall down to the top of the testicles.



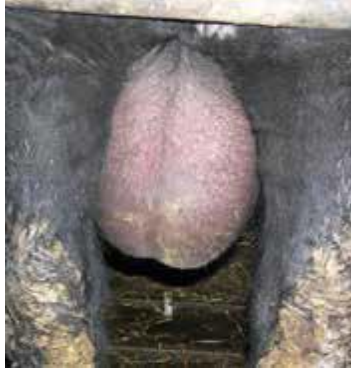Thickening of the neck and spermatic cords may be due to conditions such as scrotal hernia, varicocele, abscesses, or simply excessive fat.



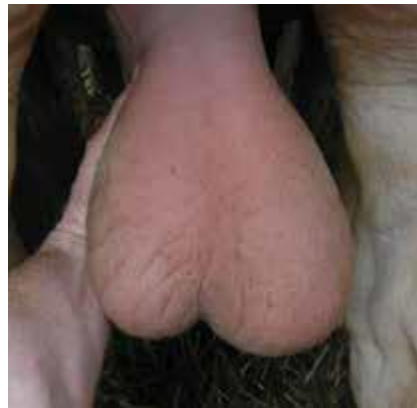The testicles should be symmetrical and any significant difference in shape or size should be noted.

### ❖ **Orchitis**

Inflammation of the testicles (orchitis) can be unilateral or bilateral. Acute orchitis will present with hot swollen testicle(s), with concurrent hydrocele and edema making palpation difficult.



Chronic orchitis will lead to enlargement and change of testicular shape.



Often the affected testicle may appear rounded and tense. There may be pain on palpation in some cases.

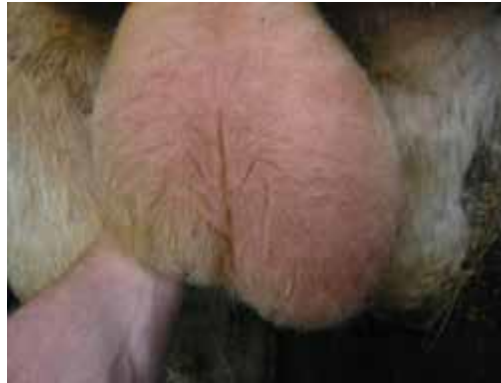### **Testicular hypoplasia;**

Testicular hypoplasia can be unilateral or bilateral as in the bull which had an SC of 26cm at four years of age. Differences in testicular size  $<20\%$  may be hard to identify, so mild unilateral hypoplasia may not always be diagnosed.



### **Testicular degeneration:**

Degeneration can be unilateral or bilateral and can be caused by many factors including overheating, stress (which reduces LH and testosterone levels), toxic, genetic, or nutritional problems. Loss of testicular tone and reduction in size.



### **Epididymitis**

The head (caput), tail (cauda), and body (corpus) of the epididymis should be palpated carefully. The caput should be obvious and in some bulls feels quite firm. The cauda should be prominent and turgid in bulls with normal sperm production. An empty, small or flaccid cauda may be an indication of blockage/segmental aplasia of the ducts or simply poor sperm production (testicular hypoplasia/degeneration).

Epididymitis is not uncommon in bulls and is normally detected during PBE without a history of clinical signs related to the acute stage of the disease.

## **V. SCROTAL CIRCUMFERENCE (SC)**

Scrotal circumference is a critical component of the PBE of bulls as the SC measurement is highly correlated to paired testes weight, daily sperm production, and semen quality. Overfeeding young bulls will not improve testicular size but may falsely increase SC due to obesity and fat in the scrotum. The subsequent

reduction in SC may be due to a combination of fat loss and/or degeneration leading to poor semen quality.

**Table 1 : SFT standards for SC**

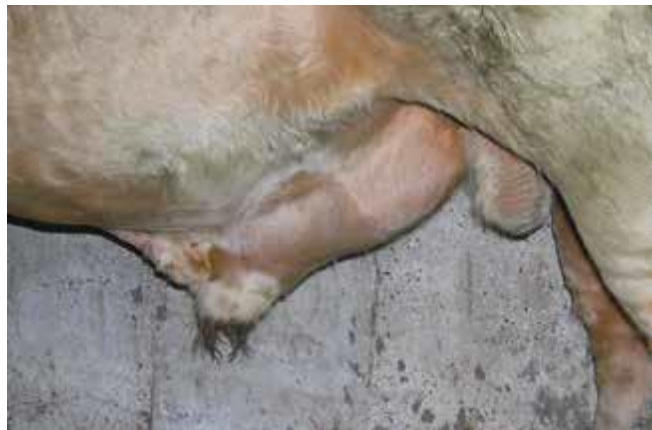Age in months	12-15	>15 ≤ 18	>18 ≤ 21	>21 ≤ 24	>24
Minimum SC	30cm	31cm	32cm	33cm	34 cm

## VI. EXAMINATION OF SHEATH AND PREPUCE

Having completed the examination of the scrotum and contents the sheath, prepuce, and penis can be inspected (normal bull). The sheath should be examined and palpated for any abnormal swellings that may be present. Lesions that may cause swelling in the sheath would include:

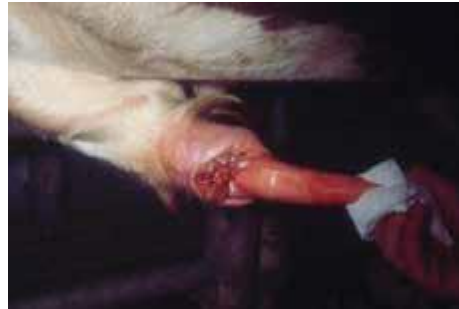### 1) Penile Rupture/Hematoma

Rupture of the tunica albuginea commonly occurs around the dorsal aspect of the sigmoid flexure leading to hematoma formation as blood leaks from the corpus cavernosum. This may be caused by the sudden movement of the cow during intromission or when young bulls are mounting each other.



### 2) Preputial Laceration/Avulsion

Traumatic tearing of the prepuce most commonly occurs where it joins the free portion of the penis. In acute cases, there will be diffuse painful swelling of the sheath just caudal to the preputial orifice. There may be bloody discharge and partial prolapse of the tip of the penis or prepuce.



In chronic/neglected cases, the damaged prepuce may become infected and contraction of the damaged tissue may cause paraphimosis and “club penis” due to constriction at the junction of the penis and prepuce.

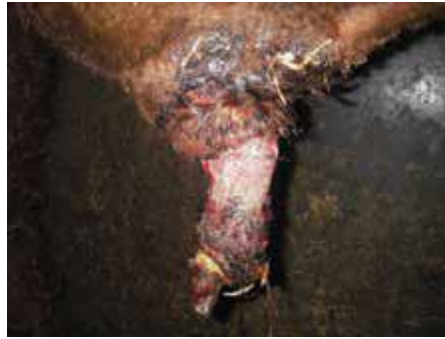

More commonly, the injury may lead to structure formation or adhesions within the sheath leading to an inability to extrude the penis and total infertility. The chronically infected cases will have a diffuse painful swelling extending for a variable way along the sheath.

### **3) Prolapse of the Prepuce:**

Failure of the retractor preputial muscle allows preputial epithelium to protrude beyond the preputial orifice possibly leading to traumatic damage. Preputial epithelium may be prolapsed permanently leading to secondary trauma and

infection. This can cause infertility as stenosis of the prepuce develops preventing full extrusion of the penis (phimosis).



## VII. EXAMINATION OF THE PENIS

Many problems can affect the bull's penis that may be detected during routine PBE. A bull should not be certified suitable for breeding unless the penis has been visualized during the PBE as problems such as papilloma and hematomata.



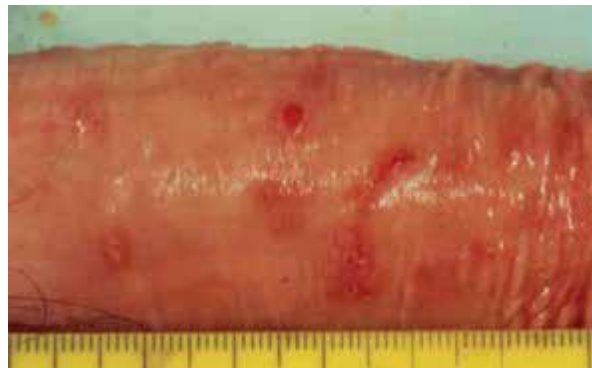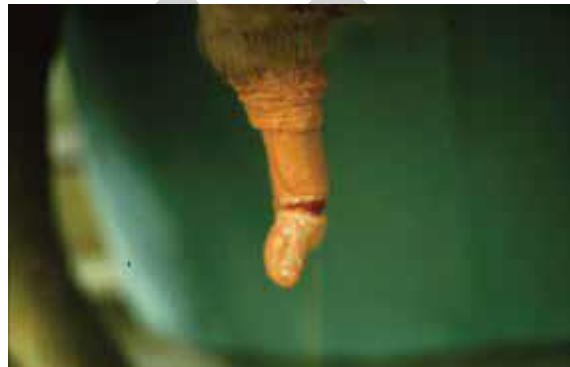### ❖ Penile Deviations

The most common deviation of the penis in bulls is a premature spiral deviation or a “corkscrew” penis.



### ❖ Traumatic injury to the free end of the penis

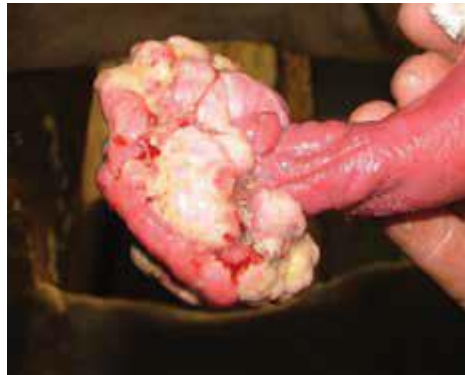This may occur along with preputial injury or in isolation. Penile lacerations may heal well by second intention and treatment is rarely required. Occasionally problems may be caused by damage extending into the urethra or damage to the dorsal nerve leading to desensitization of the tip of the penis. Hair rings can cause necrosis of the distal penis if neglected.



### ❖ Viral Fibro papilloma (warts)

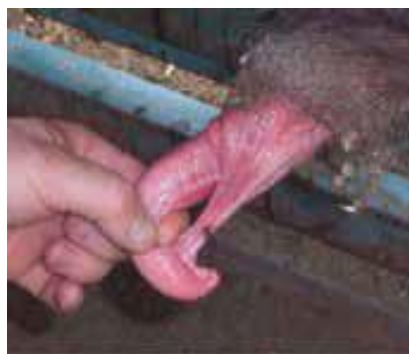

Fibro papilloma is a large broad-based cauliflower-like lesion on the glans penis and prepuce which may prevent intromission due to the size of the lesion and associated discomfort. Secondary superficial bacterial infection of papilloma is common and may lead to bleeding/discharge from prepuce.



#### ❖ **Persistent Penile Frenulum**

A rare congenital problem identified in young bulls caused by a failure of complete separation of the fused penis and prepuce at puberty. A band of tissue extends from the ventral prepuce to the tip of the penis causing deviation of the tip of the penis during attempted service.



#### ❖ **Failure of Erection:**

Bulls can develop erection failure or partial erection causing failure of intromission. Erection failure must be confirmed during natural service observation. The most common cause of erection failure when libido is normal is

the presence of vascular shunts between the corpus cavernosum and other structures preventing normal intra-cavernosal blood pressure required to achieve or maintain an erection.

## VIII. EXAMINATION OF THE INTERNAL ACCESSORY SEX GLANDS:

After the physical examination of the external genitalia, the next stage in the physical examination of the reproductive tract is rectal palpation to check for abnormalities of the accessory sex glands. The bulbourethral glands are embedded in the urethral muscle near the anal region and are not palpable. On the floor of the pelvis working from caudal to cranial the pelvic urethra surrounded by the firm urethral muscle is felt and the prostate is located as a firm transverse ring-like band of tissue on either side of which lie the paired seminal vesicles.

The vesicular glands should be uniform in size, lobulated, turgid and mobile, and non-painful on palpation. They enlarge with an age of bull. The ampulla of the ductus deferens is narrow tubular structures that lie cranial to the prostate and continue into the ductus deferens which leave the abdomen via the inguinal rings. While infection of any of the accessory sex glands is possible the most common abnormality detected during rectal examination is seminal vasculitis (vesicular adenitis).